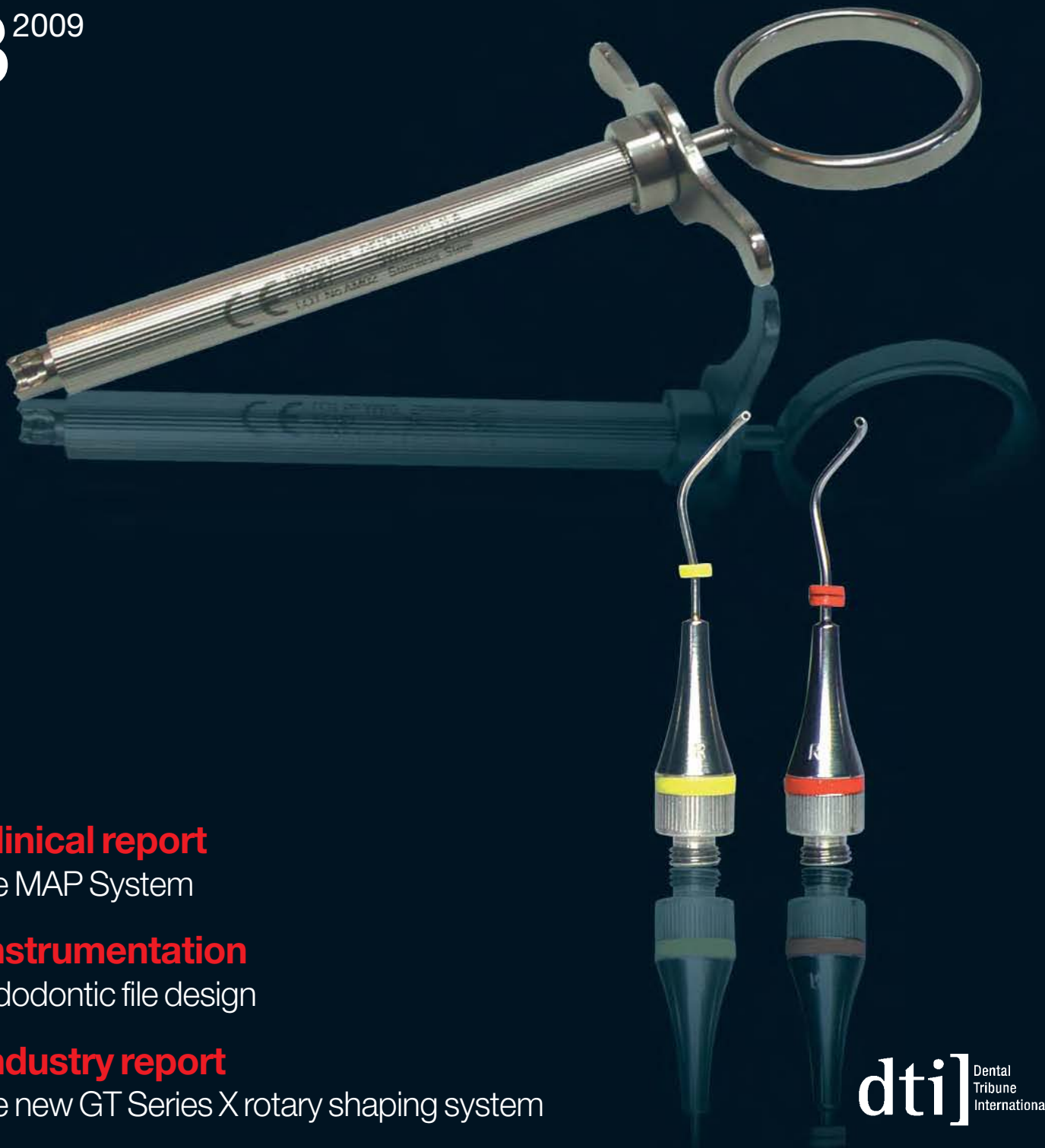

roots

international magazine of endodontology

3²⁰⁰⁹



_clinical report

The MAP System

_instrumentation

Endodontic file design

_industry report

The new GT Series X rotary shaping system

The **MAP System**: A perfect carrier for MTA in clinical and surgical endodontics

Authors_Dr Arnaldo Castellucci & Dr Matteo Papaleoni, Italy

Fig. 1_White ProRoot MTA (Dentsply Tulsa Dental).

Fig. 2_Dovgan Carriers (Quality Aspirators).

Fig. 3_The carrier described by Dr Edward Lee.

Fig. 4_The pre-measured aliquot of MTA is easily delivered into the root-end preparation using the Lee Carrier. (Image courtesy of Dr John Stropko)

Fig. 5_The Micro Apical Placement System.

Fig. 6_The bayonet catch for connecting the exchangeable needles.

Fig. 7_The straight needles for non-surgical endodontics.

Many materials are used to seal the root canal system from the oral cavity and the periradicular tissues. These include amalgam, zinc-oxide-eugenol-based cements, such as SuperEBA (H.J. Bosworth), IRM (Caulk) and Cavit. The main disadvantage of these materials is their sensitivity to the presence of moisture.¹

However, it is well known and accepted that isolation of the operative field for moisture control represents a significant problem in clinical dentistry, in general, and in restorative dentistry and endodontics, in particular. The root canal system to be obturated must be dry in order to obtain a good seal, and contamination with blood must be avoided. During a direct pulp capping procedure, haemorrhage must be controlled. When at-

tempting to seal a root perforation, a dry field is essential. Furthermore, the retro-preparation must be absolutely dry during apical surgery.

Recently, Torabinejad et al.² developed a new cement—Mineral Trioxide Aggregate (ProRoot MTA, Dentsply Tulsa Dental; Fig. 1). This cement appears to have all of the characteristics of an ideal cement that can create a seal between the root canal system and the oral cavity (mechanical and carious pulp exposures), as well as between the root canal system and the periodontium (iatrogenic perforations, open apices, resorbed apices, root-end preparations).

This cement is different to other materials currently in use because of its bio-compatibility,

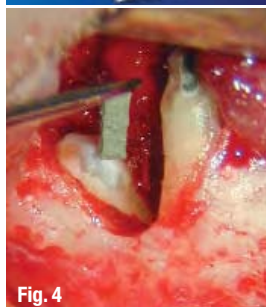
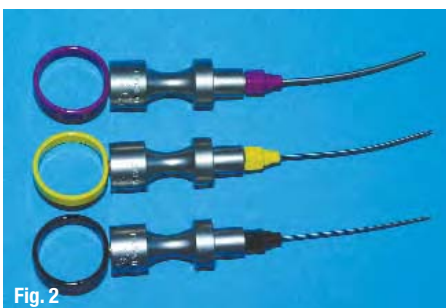
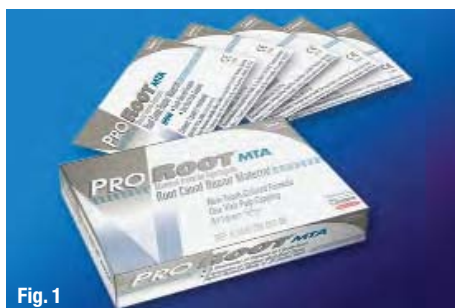

Fig. 8

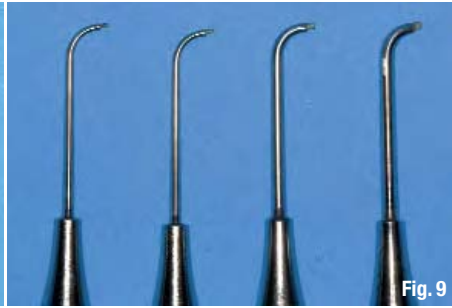


Fig. 9



Fig. 10




Fig. 11




Fig. 12




Fig. 13a



Fig. 13b

Fig. 14

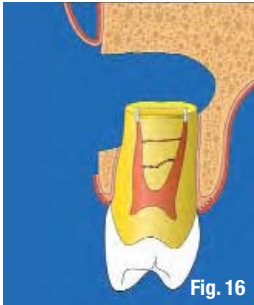

Fig. 16

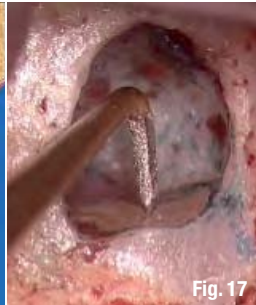

Fig. 17

open apices, or protect the pulp in direct pulp capping are inevitably in contact with blood and other tissue fluids. Moisture may be an important factor, owing to its potential effect on the physical properties and sealing ability of the restorative materials.³ As shown by Torabinejad et al.,³ MTA is the only material that is unaffected by moisture or blood contamination.

Fig. 8_ The triple-angle needle for surgical endodontics in posterior teeth.

Fig. 9_ The single-angle needle for surgical endodontics in anterior teeth.

Fig. 10_ Dispenser for filling material.

Fig. 11_ The intra-cannular plunger of the angled needles is made of PEEK.

Fig. 12_ The intra-cannular plunger of the straight needles is made of NiTi.

Figs. 13a & b_ Cleaning curettes of different sizes (a). The tip at higher magnification (b).

Fig. 14_ A 'miniature' contra-angle—still 11 mm long!

Fig. 15_ ProUltra Surgical Tips (Dentsply Maillefer).

Fig. 16_ The root apex is cut at a 90° angle.

Fig. 17_ The ultrasonic tip is ready to work along the axis of the root canal.

antibacterial and sealing properties, and marginal adaptation, but primarily because of its hydrophilic nature.²

Materials used to repair perforations, seal the retro-preparation in surgical endodontics, close

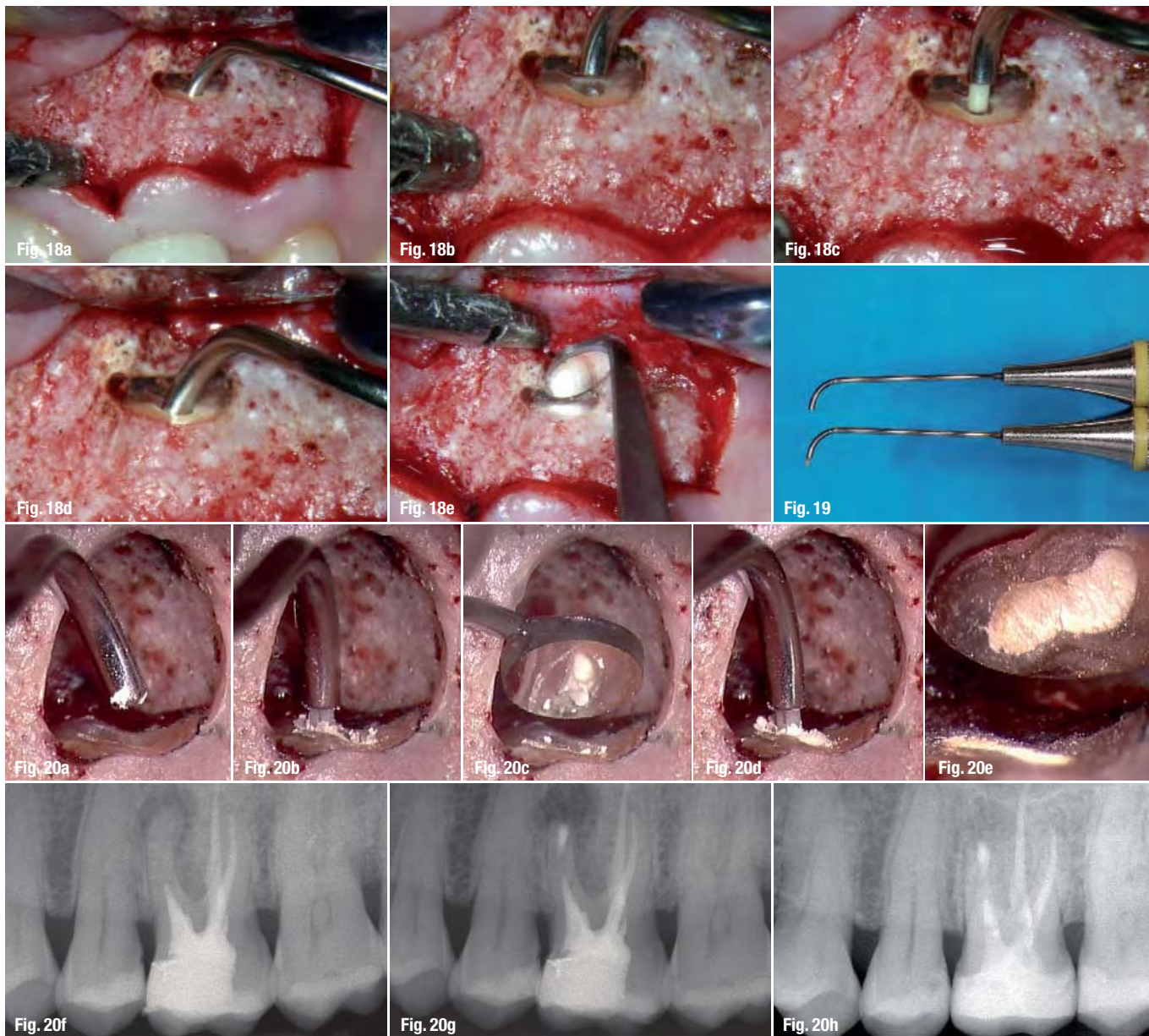
The presence or absence of blood appears not to affect the sealing ability of the MTA. In fact, MTA sets only in the presence of water.² MTA is considered today to be the material of choice for direct pulp capping,⁴ closing open apices,⁵ repairing perforations,⁶ and sealing the retro-preparations in surgical endodontics.

A disadvantage of the material is that it is not easy to handle and when it was first introduced to the market, there was no appropriate carrier to position it during different applications.

The first carrier that became available was the Dovgan Carrier (Quality Aspirators; Fig. 2). But even though the needles were bendable, the carrier was



Fig. 15



Figs. 18a–e The pre-fitted needle is carrying the filling material.
Fig. 19 The intra-cannular plunger inside the needle is intentionally longer than the needle itself.
Figs. 20a–h The carrier also functions as a plugger, beginning to compact the filling material in the deepest portions of the prepared cavity (a–e). Preoperative radiograph (f). Post-operative radiograph (g). Two-year recall (h).

not comfortable to use during surgery. In 2000, another carrier was proposed by Dr Edward Lee,⁷ but its use was limited to surgery (Figs. 3 & 4). The Micro Apical Placement (MAP) System, a new universal carrier with special needles that can be used both in clinical and in surgical endodontics, was recently introduced by Produits Dentaires SA (Fig. 5).⁸

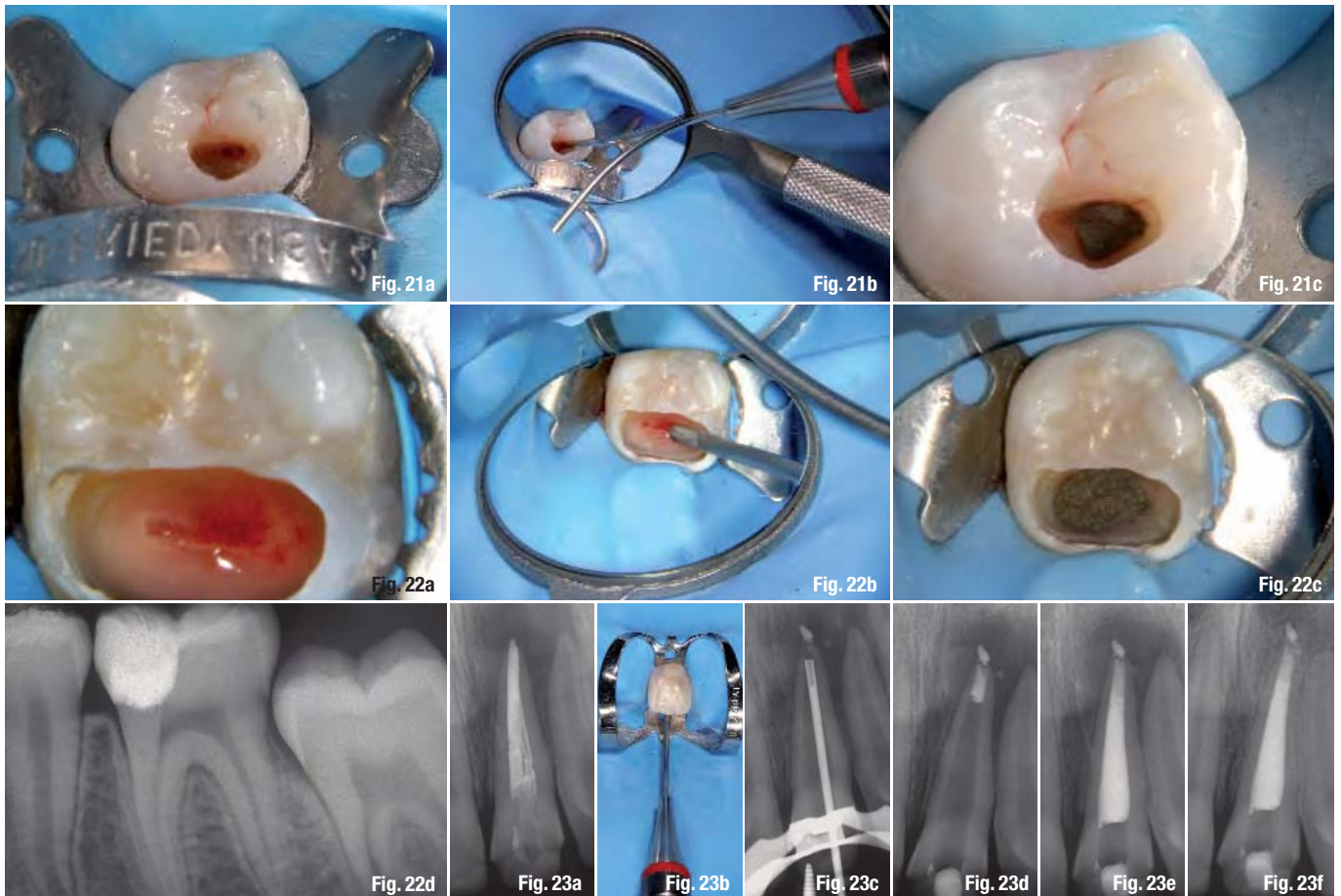
The instrument

The system consists of a stainless-steel applicator with a bayonet catch (Fig. 6) for several exchangeable applicator cannulas (needles). The straight and curved needles (Fig. 7) are designed for non-surgical endodontics, while the triple-angle needles (Fig. 8), developed in cooperation with Dr Bernd Ilgenstein, and

single-angle needles (Fig. 9) are best indicated for surgical endodontics.

The surgical needles are available in two variants, right-angled and left-angled, each with two external diameters, 0.9 mm (yellow) and 1.1 mm (red). The internal diameter of the canulas is 0.6 mm (yellow) and 0.8 mm (red), which allows for sufficient portions of the retro-filling material to be applied successively.

The filling material can be taken from a dispenser/well (Fig. 10). The intra-cannular plungers of the angled needles are made of PEEK (Polyether Ether-Ketone), a polymer used for medical purposes (Fig. 11), and the plungers of the straight and curved needles are made of NiTi (Fig. 12). Residue of material inside the



cannulas can easily be removed with a cleaning curette (Fig. 13).

Surgical applications

For many years, the root end was surgically prepared by drilling a Class 1 preparation into the dentine, using a straight slow-speed handpiece or a 'miniature' contra-angle handpiece with small round or inverted-cone carbide burs (Fig. 14). This approach had many disadvantages, mainly the inability to create a preparation in the longitudinal axis of the root canal and to clean the buccal surface of the root end. In attempting to give sufficient retention to the cavity, there was always the risk of a palatal or lingual perforation, and the procedure became increasingly difficult, as the root canal became increasingly difficult to reach. The smallest burs were always too large compared to the diameter of the root canals, and the large cavities were therefore more difficult to seal. For the same reason, retro-preparations often failed to include isthmus areas.

The introduction of ultrasonic root-end preparation made it possible to obtain what is defined as the ideal retro-preparation: a Class 1 preparation at least 3 mm into the root dentine, with walls par-

allel to a coincident with the anatomic outline of the pulpal space.^{9,10} In order to do this, special ultrasonic tips were developed to enable the clinician to reach every root in all clinical situations (Fig. 15). The use of the specifically designed retro-tips allows the operator to clean the root canal from an apical approach, leaving clean dentinal walls not only on the lingual or palatal side, but also on the buccal side, which was impossible to clean with the previous techniques. The cavity can now be made 3 mm deep without the necessity of making undercuts, as there is no need for further retention.

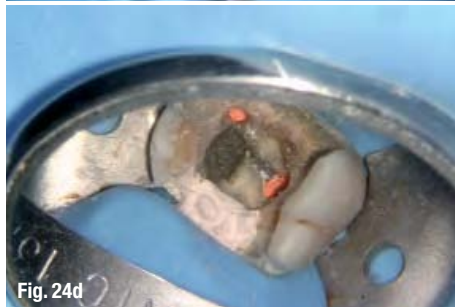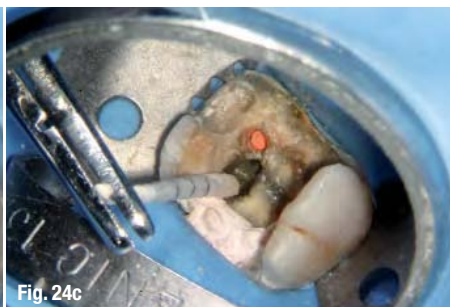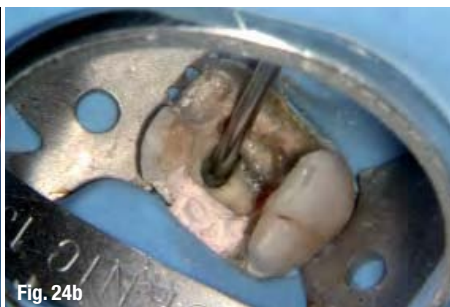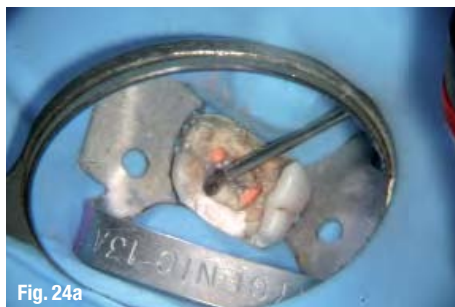
The retro-tips are of the same size as, or even smaller than, the original size of the root canal; thus, that the retro-preparation can be easily and predictably sealed with respect to the original anatomy. The isthmus area can now be included in the preparation, without damaging or weakening the root, while being extremely conservative in the mesio-distal dimension.

The root surface is no longer cut with a bevel at 45° but rather at an almost 90° angle (Figs. 16 & 17). This involves the need for a specific carrier in order to deliver the retro-filling material at a 90° angle (Figs. 18a–e). The MAP System is the perfect

Figs. 21a–c—The straight needle is carrying the MTA over a pulp exposure of an upper second premolar to perform a direct pulp capping.

Figs. 22a–d—Direct pulp capping with MTA and the MAP System. The pulp exposure (a). The straight needle is carrying the MTA over the pulp exposure (b). The MTA has been positioned and compacted (c). Two-year recall (d).

Figs. 23a–f—Use of the MAP System for the Apical Barrier Technique in the case of an open apex. Preoperative radiograph. The central incisor had previously been treated with cold lateral condensation (a). The straight needle is carrying the MTA to build the apical barrier (b). Intra-operative radiograph with the carrier in the root canal. The material in the peri-apical tissue is gutta-percha, which has been extruded during the re-treatment (c). The MTA has been positioned at the apex (d). Post-operative radiograph. The obturation has been performed using thermoplastic gutta-percha (e). 15-month recall (f).



Figs. 24a–d The straight needle is carrying the MTA to seal a perforation on the floor of the upper first molar.

carrier for this purpose, having several needles in different sizes and with different angulations. The single-angle needles are best indicated for anterior teeth, while the triple-angle needles are best indicated for posterior teeth. They are available in two variants, right-angled and left-angled, for an easier treatment

of hard-to-reach regions (palatal canals of upper premolars and molars, lingual canals of lower molars).

The intra-cannular plunger inside the needle is intentionally longer than the needle itself (Fig. 19), so that it will not only deliver the MTA in the retro-preparation, but will also act as a plugger and thus begin to compact the material in the deepest portion of the prepared cavity (Figs. 20a–h). The risk of air bubbles can therefore be avoided. As a result, the retro-root canal filling will always be well compacted.

An advantage of using the MAP System during surgery is the perfect control of the obturating material, which will be laid in the retro-cavity without any dispersion in the surrounding bone and soft tissue.

Once the retro-cavity has been prepared using the ultrasonic retro-tips and the bleeding of the bony crypt is under control, the operator asks the dental assistant to mix the MTA to the correct consistency and then to handle the pre-fitted applicator syringe. The consistency of MTA must be neither too wet nor too dry. If the mixture is too wet, it will be difficult to compact the material in the cavity properly. If it is too dry, it will be difficult to extrude the material from the needle and the syringe may remain blocked. Should the latter be the case, it is essential to avoid pushing too hard. The PEEK plunger is insufficiently rigid and will remain bent next to the bayonet catch, and thus need to be replaced. For this reason, is always advisable to have two needles ready for use.

As previously stated, the following clinical applications for the straight needles with the NiTi plunger are indicated to carry MTA in non-surgical endodontics: during direct pulp capping (Figs. 21a–c & 22a–d), for the treatment of open apices (Figs. 23a–f), and during the repair of perforations (Figs. 24a–d).

Conclusions

The MAP System is recommended as a universal MTA carrier for use in both surgical and clinical endodontics. The triple-angle needles, specifically designed to carry the filling material in the retro-cavity during surgery, allow for easy reach of all anatomically tricky regions. The retro-filling material can be laid from the fundus of the cavity, avoiding inclusion of air bubbles. The size of the needles can perfectly fit the size of the retro-cavity, avoiding any dispersion of materials in the surrounding tissues.

author info

roots



Dr Arnaldo Castellucci graduated in medicine from the University of Florence in 1973 and specialised in dentistry at the same university in 1977. He is past president of the Italian Endodontic Society, past president of the International Federation of Endodontic Associations,

an active member of the European Society of Endodontology. He is editor of The Italian Journal of Endodontics and of The Endodontic Informer. An international lecturer, he is the author of the text *Endodonzia (Endodontics)*, now available in English. Dr Castellucci can be reached at castellucci@dada.it.